



Case report of gross hematuria in the nutcracker syndrome resolved by renocaval reimplantation

Prikaz izlječenja bolesnika sa obilnom hematurijom kod sindroma *nutcracker* primenom renokavalne reimplantacije

Igor Banzić^{*†}, Nikola Fatić[†], Siniša Pejkić^{*†}, Lazar Davidović^{*†},
Miloš Sladojević[†], Igor Končar^{*†}

^{*}Faculty of Medicine, University of Belgrade, Belgrade, Serbia; [†]Clinic for Vascular and Endovascular Surgery, Clinical Center of Serbia, Belgrade, Serbia

Abstract

Introduction. Nutcracker syndrome is defined as a set of signs and symptoms secondary to compression of the left renal vein (LRV) in the acute anatomic angle between the aorta and its superior mesenteric branch. **Case report.** A 38-year-old woman with asymptomatic and “idiopathic” gross hematuria came to the Clinic for Vascular and Endovascular Surgery, Clinical Center of Serbia in Belgrade. Hematuria was documented by cystoscopy and was found to be unilateral, located to the left urethral orifice. The contrast-enhanced multidetector computed tomography (MDCT) scan showed a stenotic LRV due to the extrinsic compression in the angle formed by the ventral aorta and superior mesenteric artery (MSA), with a jet of contrast through the lumen. Considering the negative investigations for more common causes of hematuria, its incapacitating nature, and above mentioned imaging findings suggestive of the nutcracker syndrome, an indication for the open surgical correction of the LRV entrapment was established. The patient underwent reimplantation of the LRV into the more distal inferior vena cava (IVC), to relocate it out of the constrictive aortomesenteric space. Intraoperative findings were notable for blood flow turbulence in the LRV and hypertrophy of its tributaries, which were ligated. We presented the first published case in the Serbian literature on nutcracker syndrome with hematuria resolved by renocaval reimplantation. **Conclusion.** This case report demonstrates that renocaval reimplantation, as the open surgery technique, could be the adequate method for resolving gross hematuria in patients with nutcracker syndrome.

Key words:

renal nutcracker syndrome; diagnosis; vascular surgical procedures; renal veins; replantation; treatment outcome; serbia.

Apstrakt

Uvod. *Nutcracker* sindrom se definiše kao skup znakova i simptoma nastalih usled kompresije leve renalne vene u oštrom uglu koji formiraju aorta i gornja mezenterična arterija. **Prikaz bolesnika.** Bolesnica, stara 38 godina, sa obilnom, asimptomatskom i idiopatskom hematurijom primljena je na lečenje u Kliniku za vaskularnu i endovaskularnu hirurgiju Kliničkog centra Srbije u Beogradu. Hematurija je potvrđena cistoskopijom. Nađeno je da se radi o unilateralnoj hematuriji lokalizovanoj na levom ureteralnom orificijumu. Multidetektorskom kompjuterizovanom tomografijom (MDCT) angiografijom utvrđena je stenoza leve renalne vene, kao posledica kompresije, u uglu koji formiraju gornja mezenterična arterija i ventralna strana aorte. Uzimajući u obzir negativne nalaze o uzrocima hematurije, njen onesposobljavajući karakter i prethodno pomenuti nalaz MSCT angiografije, postavljena je sumnja na *nutcracker* sindrom kao i odluka o operativnom lečenju. Kako bi se leva renalna vena dislocirala iz aortomesenteričnih klešta, učinjena je njena reimplantacija udaljenije na venu kavu. Intraoperativni nalaz potvrdio je turbulentan tok u levoj renalnoj veni, torturozitet i našikanost njenih povezanih pritoka. Ovo je prvi primer *nutcracker* sindroma u Srbiji koji je izlečen renokavalnom reimplantacijom. **Zaključak.** Rad ukazuje na adekvatnu vrednost renokavalne reimplantacije, kao otvorene hirurške tehnike, u lečenju obilne hematurije kod bolesnika sa *nutcracker* sindromom.

Ključne reči:

nutcracker sindrom, renalni; dijagnoza; hirurgija, vaskularna, procedure; vv. renales; replantacija; lečenje, ishod; srbija.

Introduction

The nutcracker syndrome is defined as a set of signs and symptoms secondary to compression of the left renal vein (LRV) in the acute anatomic angle between the aorta and its superior mesenteric branch. Extrinsic compression of the left kidney main venous drainage leads to local venous hypertension, with the development of collaterals, pelvic varicose, and gonadal tributary reflux, resulting in hematuria, left flank pain and symptoms of pelvic congestion¹⁻³.

We presented the first published case in the Serbian literature of the nutcracker syndrome with hematuria resolved by renocaval reimplantation.

Case Report

A 38-year-old woman of two was referred to our clinic because of the chronic "idiopathic" gross hematuria, which occurred intermittently for the last ten years, but recently became persistent and demanded blood transfusions for the correction of anemia, prompting more extensive diagnostic investigation. Besides hematuria, the patient complained of no other symptoms, and her past medical, surgical and family history was noncontributory. Except for anemia (laboratory findings: $Er\ 3.2 \times 10^{12}/L$; $Hb\ 104\ g/L$; $Ht\ 0,32l/L$; $MCV\ 80\ fl$; $MCH26\ pg$; $MCHC\ 300\ g/L$) and asthenic constitution,

physical examination was unremarkable, with soft and no tender abdomen, without any signs of peripheral vascular lesions, and novulvar varicosities. The patient underwent repetitive urine cultures and excretory urography with negative results. Hematuria was documented by cystoscopy and was found to be unilateral, located to the left urethral orifice. Urine cytology was negative for malignancy. After we excluded urological, nephrology, gynecological and oncological reasons for hematuria, contrast-enhanced multidetector computed tomography (MDCT) revealed a hyperacute aortomesenteric angle with impingement of the left renal vein, findings that were corroborated by the contrast inferior cava venography with selective catheterization of the left renal vein. Dilated and tortuous adrenal and gonadal venous tributaries were also noted.

The contrast-enhanced MDCT scan showed a stenotic LRV due to the extrinsic compression in the angle formed by the ventral aorta and superior mesenteric artery (MSA), with a jet of contrast through the lumen (Figures 1 and 2). Color Doppler ultrasonography and selective retrograde left renal venography showed dilatation of the distal part of the LRV and gonadal vein with pelvic varicosities (Figure 3).

Considering the negative investigations for more common causes of hematuria, its incapacitating nature, and abovementioned imaging findings suggestive of the nutcracker syndrome, an indication for the open surgical correction of

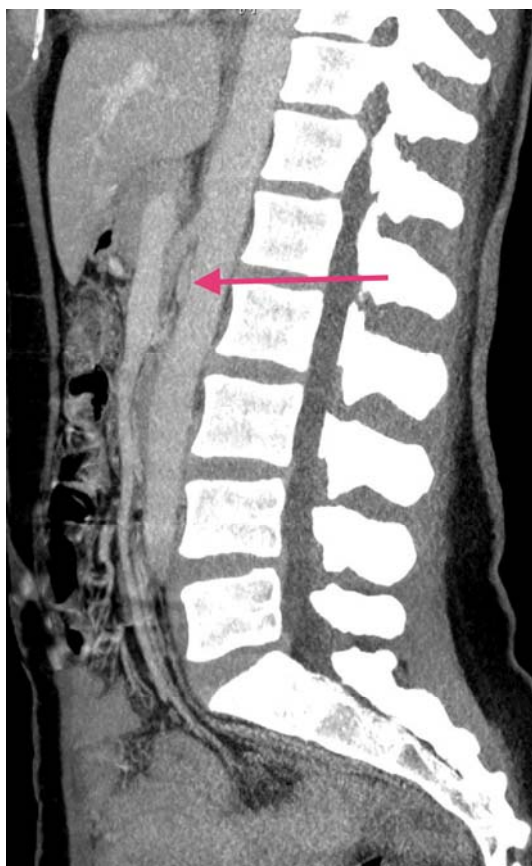


Fig. 1 – Compression of the left renal vein between the aorta and the superior mesenteric artery, multidetector computed tomography (MDCT) longitudinal section

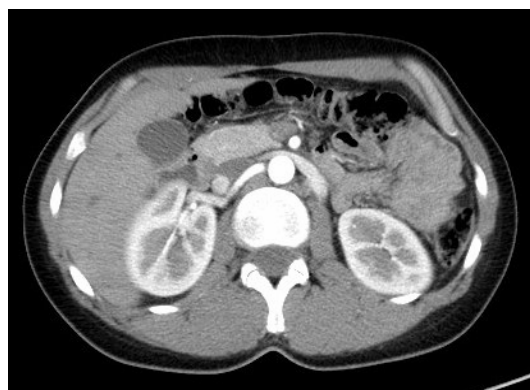

Fig. 2 – Compression of the left renal vein between the aorta and the superior mesenteric artery, multidetector computed tomography (MDCT) transverse section

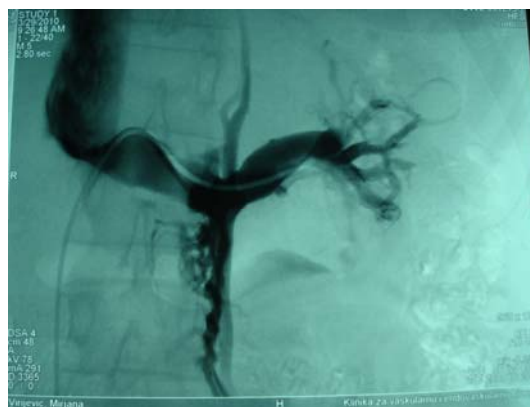


Fig. 3 – Selective retrograde left renal venography showing dilatation of the distal part of the left renal vein (LRV) with pelvic varicosities

the LRV entrapment was established. Under general anesthesia, using midline laparotomy approach, the patient underwent reimplantation of the LRV into the more distal inferior vena cava (IVC), to relocate it out of the constrictive aortomesenteric space. Intraoperative ultrasound findings were notable for blood flow turbulence in the LRV and hypertrophy of its tributaries, which were ligated.

Discussion

The true incidence of the symptomatic nutcracker syndrome in a general population is unknown. It seems that this syndrome is most common in women in the third and fourth decades of life⁴. In their pathologic study, Macmahon and Latorraca⁵ elucidated an association between the nutcracker syndrome and hematuria.

According to the current international experience, there are several ways of solving this problem – by nephrectomy, nephropexy, renocaval reimplantation of the LRV or LRV stenting^{4, 6-16}. We opted for the renocaval reimplantation as the most commonly used method, and because of our

experience with open surgical procedures and lack of endovascular material at that moment. The LRV was excised from the entry site at the IVC and reanastomosed with the IVC 4 cm below the original anatomic site. There were no intraoperative or early postoperative complications (< 30 days). During the postoperative follow-up of one and a half year macrohematuria despaired. According to the previously published reports, in most similarly treated cases of the nutcracker syndrome hematuria resolved in up to 5 months of follow-up. Control duplex-sonography, CT venography, and conventional contrast venography confirmed correct hemodynamics and morphology of the reconstructed LRV. Laboratory findings restored to the normal range (Er $4.28 \times 10^{12}/L$; Hb 130 g/L; Ht 0.420 L/L; MCV 85 fl; MCH 31.1 pg; MCHC 330 g/L).

Conclusion

This case report demonstrates that renocaval reimplantation, as the open surgery technique, could be the adequate method for resolving gross hematuria in patients with nutcracker syndrome.

R E F E R E N C E S

1. Rudloff U, Holmes RJ, Prem JT, Faust GR, Moldwin R, Siegel D. Meso-aortic compression of the left renal vein (nutcracker syndrome): Case reports and review of the literature. *Ann Vasc Surg* 2006; 20(1): 120–9.
2. Kim JY, Job JH, Choi HY, Do YS, Shin SW, Kim DI. Transposition of the left renal vein in nutcracker syndrome. *Eur J Vasc Endovasc Surg* 2006; 31(1): 80–2.
3. Rassi I, Khabbaz Z, Chelala D, Jebara VA. A new variant of the posterior nutcracker phenomenon. *J Vasc Surg* 2010; 51(5): 1279.
4. Ahmed K, Sampath R, Khan MS. Current trends in the diagnosis and management of renal nutcracker syndrome: A review. *Eur J Vasc Endovasc Surg* 2006; 31(4): 410–6.
5. Macmahon HE, Latorraca R. Essential renal hematuria. *J Urol* 1954; 71(6): 667–76.
6. Hobenfellner M, Steinbach F, Schultz-Lampel D, Schantzen W, Walter K, Cramer BM, et al. The nutcracker syndrome: new aspects of pathophysiology, diagnosis and treatment. *J. Urol* 1991; 146(3): 685–8.
7. Zhang H, Zhang N, Li M, Jin W, Pan S, Wang Z, et al. Treatment of six cases of left renal nutcracker phenomenon: Surgery and endografting. *Chin Med J* 2003; 116(11): 1782–4.
8. Shokeir AA, Diasty TA, Ghoneim MA. The nutcracker syndrome: New methods of diagnosis and treatment. *Br J Urol* 1994; 74(2): 139–43.
9. Stewart BH, Reiman G. Left renal venous hypertension "nutcracker" syndrome. Managed by direct renocaval reimplantation. *Urology* 1982; 20(4): 365–9.
10. Scultetus AH, Villavicencio JL, Gillespie DL. The nutcracker syndrome: its role in the pelvic venous disorders. *J Vasc Surg* 2001; 34(5): 812–9.
11. Neste MG, Narasimham DL, Belcher KK. Endovascular stent placement as a treatment for renal venous hypertension. *J Vasc Interv Radiol* 1996; 7(6): 859–61.
12. Park YB, Lim SH, Ahn JH, Kang E, Myung SC, Shim HJ, et al. Nutcracker syndrome: Intravascular stenting approach. *Nephrology, dialysis, transplantation* 2000; 15(1): 99–101.
13. Wei S, Chen Z, Zhou M. Intravenous stent placement for treatment of the nutcracker syndrome. *J Urol* 2003; 170(5): 1934–5.
14. Segawa N, Azuma H, Iwamoto Y, Sakamoto T, Suzuki T, Ueda H, et al. Expandable metallic stent placement for nutcracker phenomenon. *Urology* 1999; 53(3): 631–3.
15. Barnes RW, Fleisher HL, Redman JF, Smith JW, Harshfield DL, Ferris EJ. Meso-aortic compression of the left renal vein (the so-called nutcracker syndrome): Repair by a new stenting procedure. *J Vasc Surg* 1988; 8(4): 415–21.
16. Reed NR, Kalra M, Bower TC, Vrtiska TJ, Ricotta JJ, Glowiczki P. Left renal vein transposition for nutcracker syndrome. *J Vasc Surg* 2009; 49(2): 386–93.

Received on April 1, 2015.

Revised on August 28, 2015.

Accepted on September 2, 2015.

Online First May, 2016.